

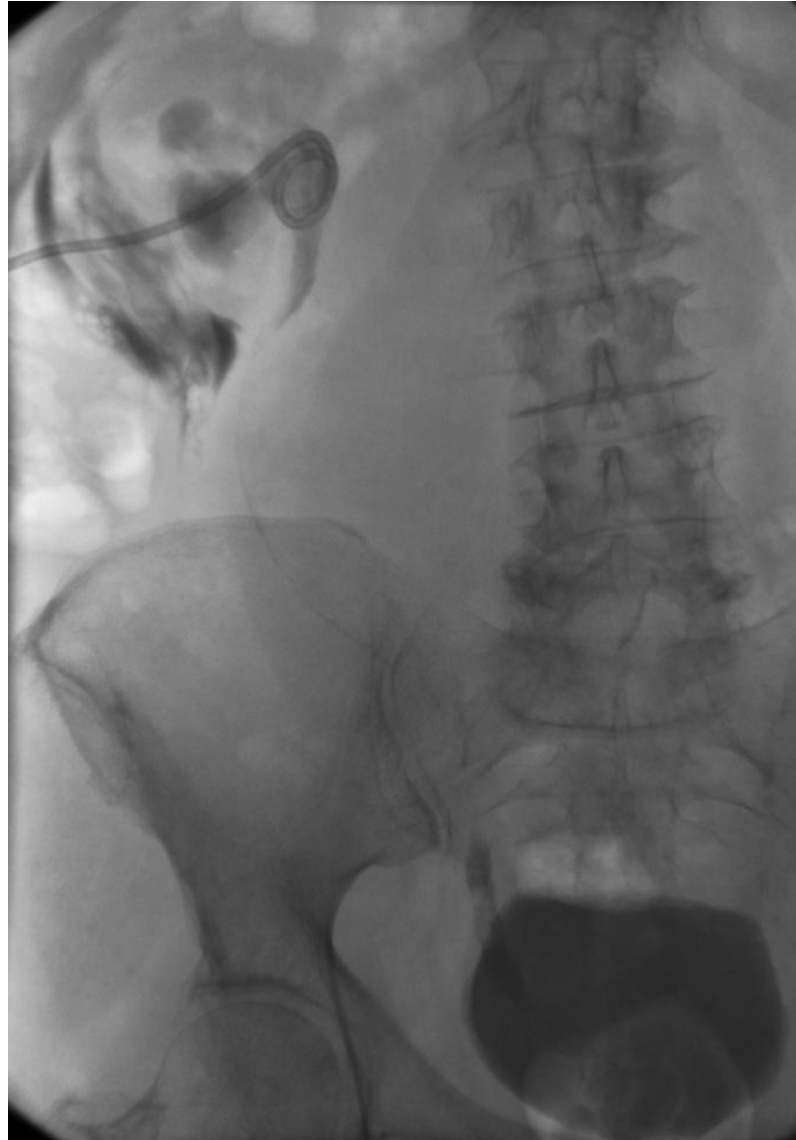## **N-001 Non-Vascular IR**

Sepsis and Renal Failure

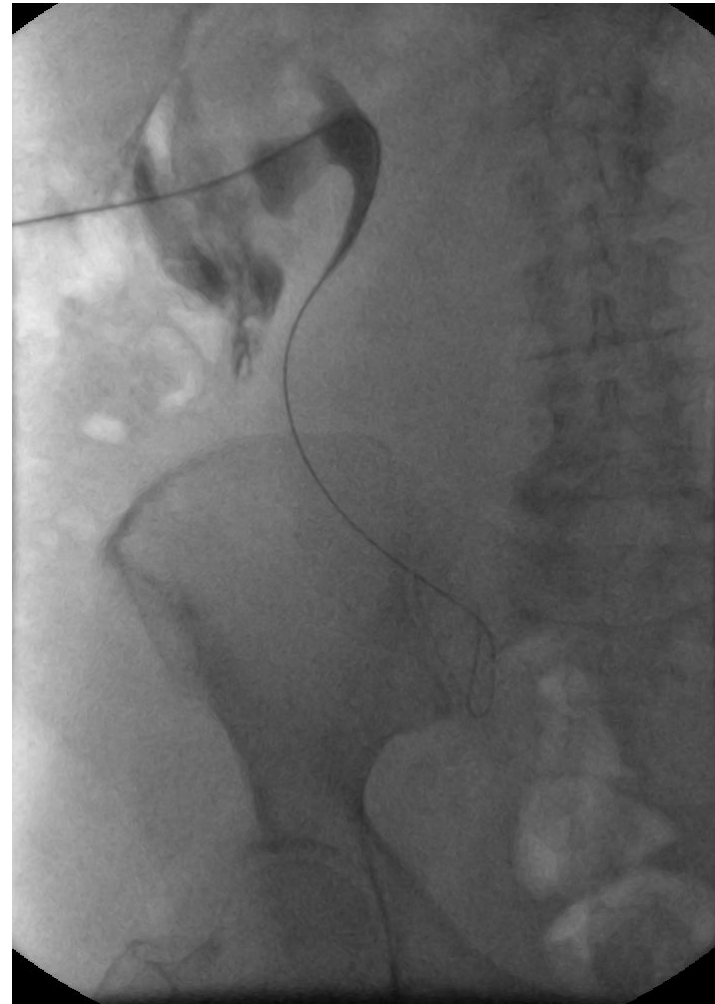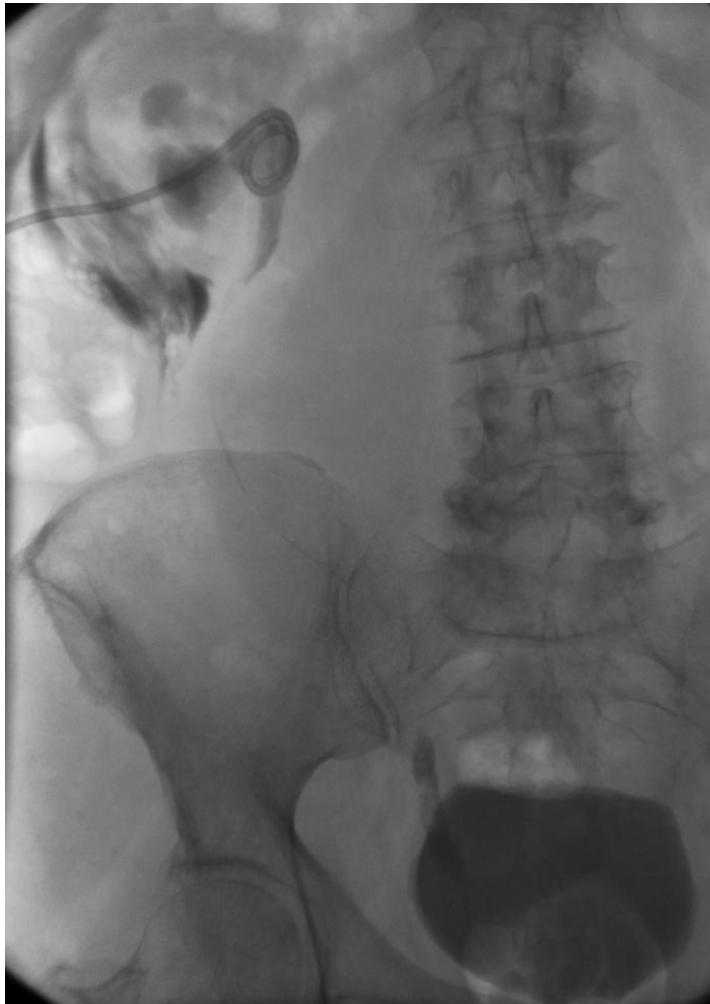## Medical History

- 70-year-old female patient with right ureteric obstruction secondary to a large retroperitoneal metastatic lymph node mass from a malignant uterine sarcoma.
- The patient was septic with an elevated creatinine and urea.
- Ureteroscopic catheterisation was impossible

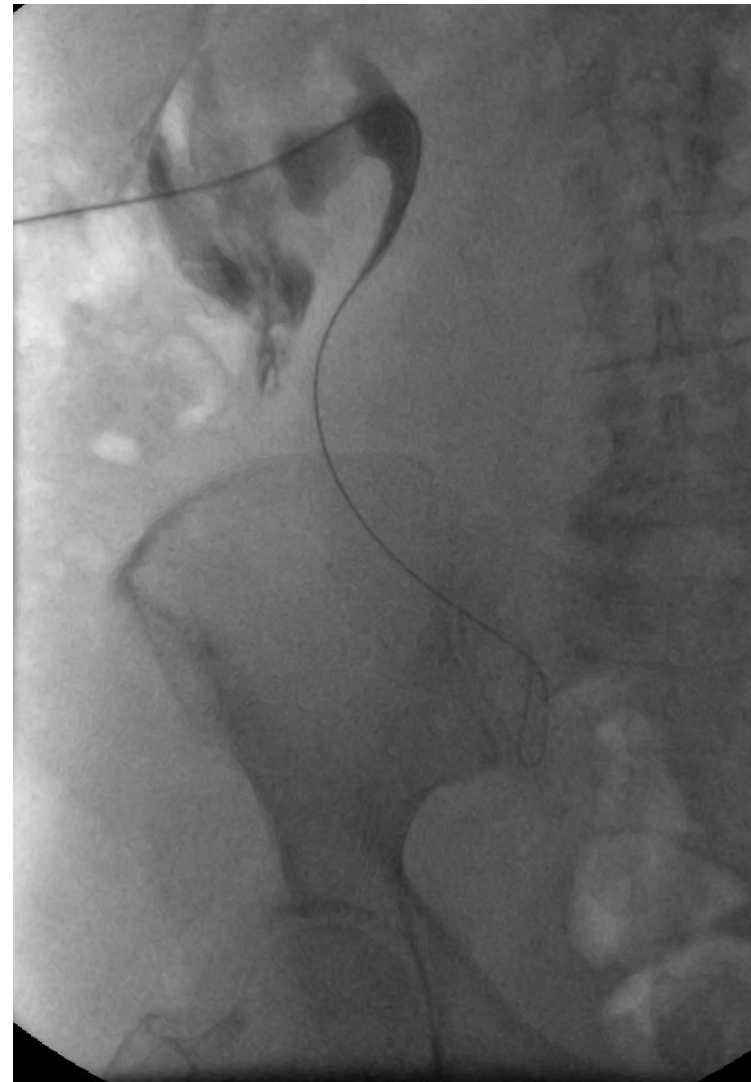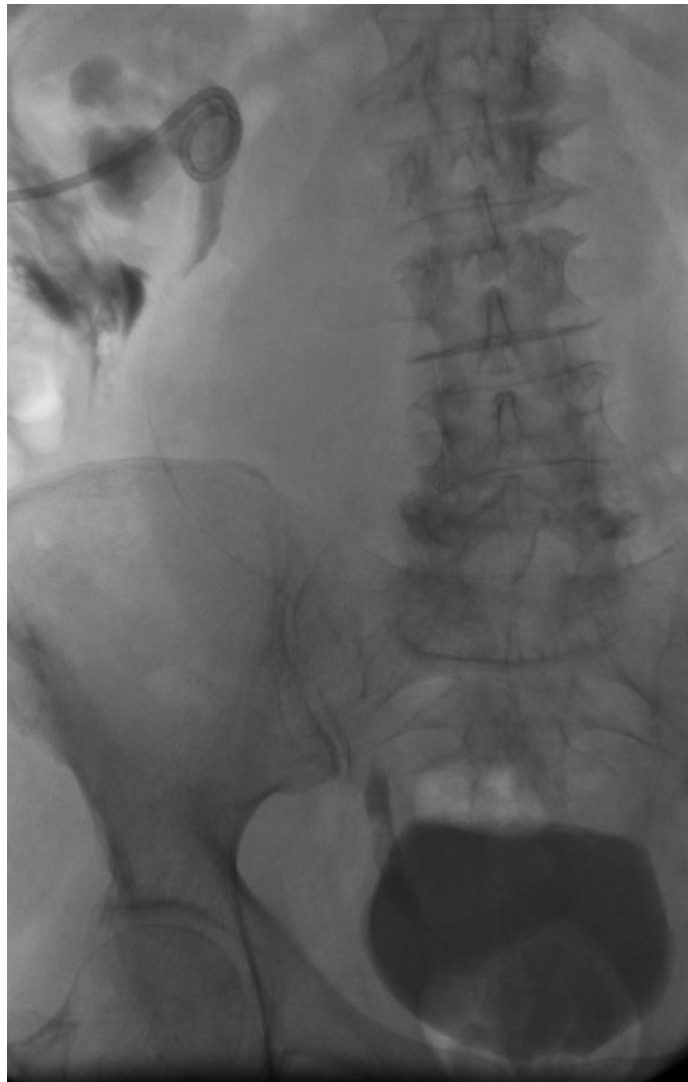Q 1: What is the patient preparation for antegrade ureteral stenting?



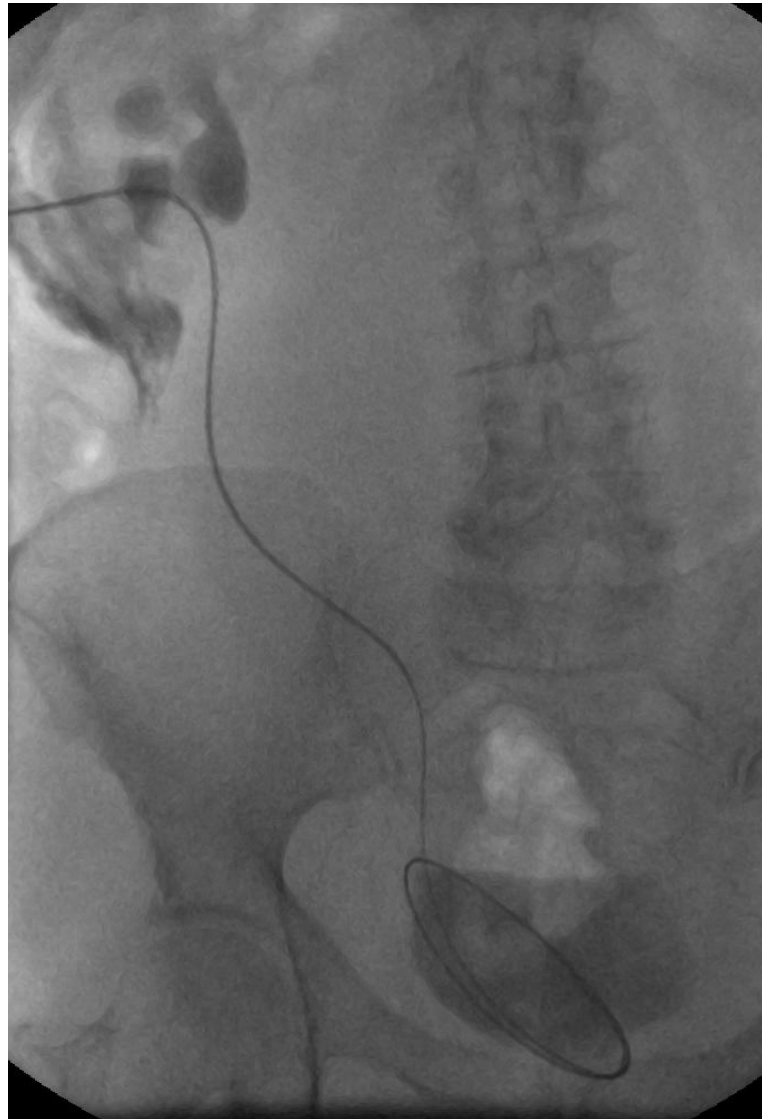
Q 2: What do these images show?



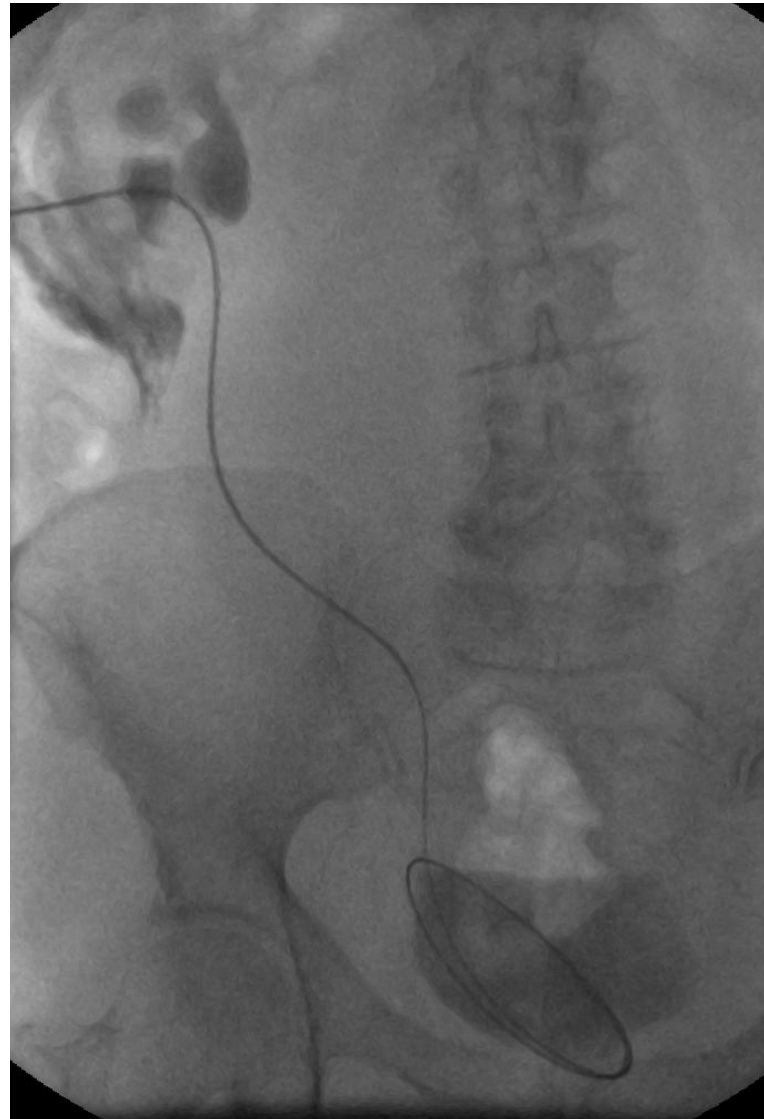
Q 3: How would you cross the stenosis following the nephrostomy?



Q 4: Describe the main steps in placing a ureteric stent



Q 5: What are the main complications of ureteric stenting?



You have completed this case.

Please move on to the next!